

# Supernumerary Frenulum on the Dorsum of the Penis: A Case Report

PRABHAKAR ULAGANATHAN

(CC) BY-NC-ND

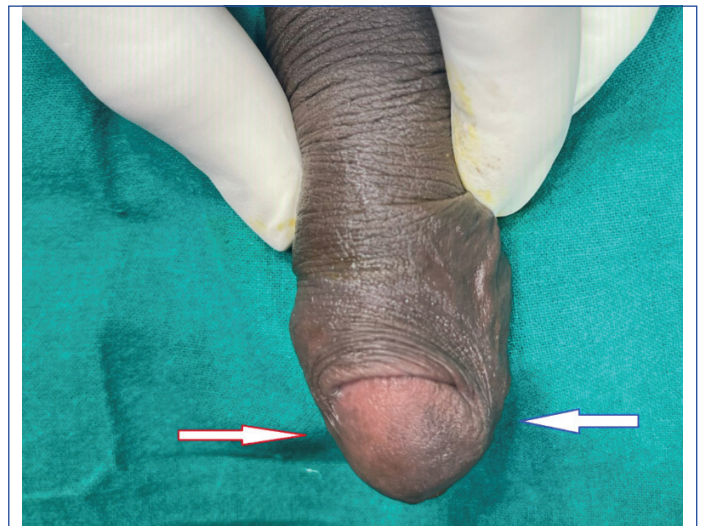## ABSTRACT

A supernumerary frenulum on the dorsal aspect of the penis, without penile torsion, is a rare condition. The present case report presents a 29-year-old male who experienced pain during sexual intercourse. He noticed a band of tissue on the underside of his foreskin that prevented the retraction of his prepuce during his first attempted sexual intercourse. The present case illustrates a supernumerary frenulum, which is an additional band of tissue on the dorsal side of the penis, alongside the normally positioned frenulum. It is a natural anatomical variation. The high prevalence of neonatal religious circumcision and general ignorance likely contribute to the under-reporting of this anomaly. This condition can significantly impact an individual's sexual life and personal hygiene. The present case was aimed to enhance understanding of the embryology, prevalence, clinical implications and management of this anomaly.

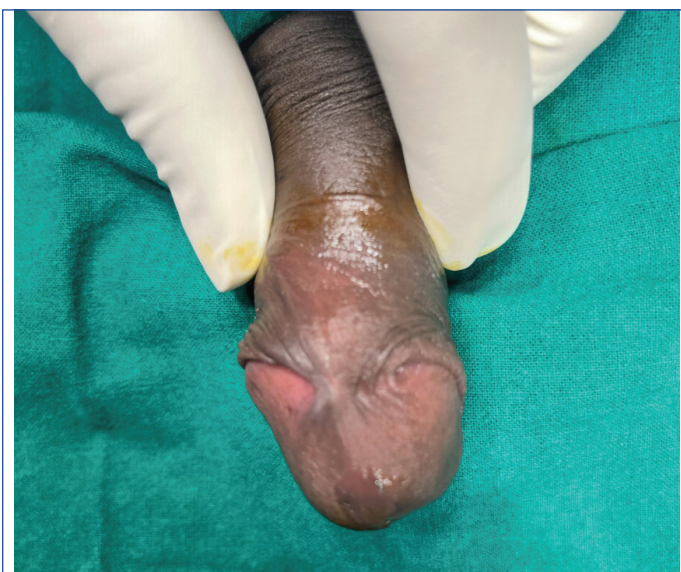**Keywords:** Circumcision, Congenital penile abnormality, Dyspareunia, Dorsal frenulum

## CASE REPORT

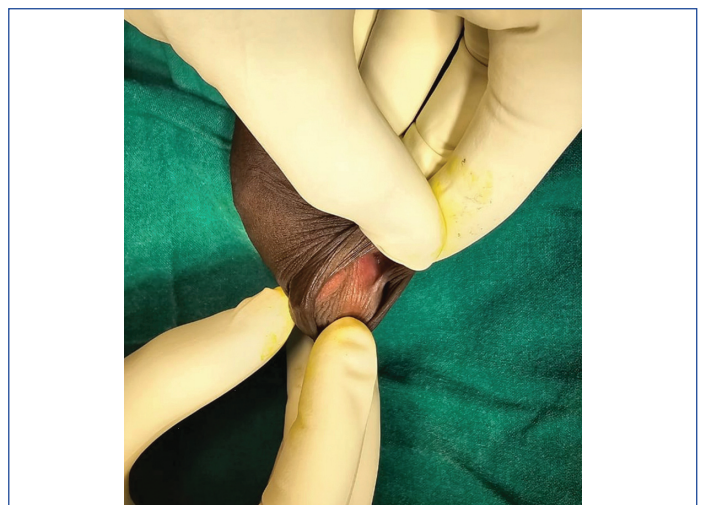
A 29-year-old male who recently got married reported difficulty retracting his foreskin and experienced discomfort during sexual intercourse, including pain during attempted intercourse. There was no history of balanoposthitis or circumcision in his childhood. Upon examination, it was observed that the prepuce over the glans penis was not retracted, and there was a distinct band of tissue located on the dorsal side, in addition to the normal ventral frenulum [Table/Fig-1-3]. This strip of tissue was found to be attached to the inner layer of the prepuce and the glans penis, and it did not extend to the corona. The genital structures, including the penis, scrotum and testes, were appropriately developed and of average size for the patient's age. There was no other notable medical or surgical history. Furthermore, no torsion of the penis or other congenital anomalies were identified. Routine investigations were performed, and nothing significant was found. The possible differential diagnosis included penile torsion, adhesions from prior circumcision, infection, or trauma.



[Table/Fig-2]: Lateral view showing supernumerary dorsal frenulum (Red arrow) and normal ventral frenulum (Blue arrow).



[Table/Fig-1]: Supernumerary frenulum on the dorsal aspect of the penis (Dorsal view).

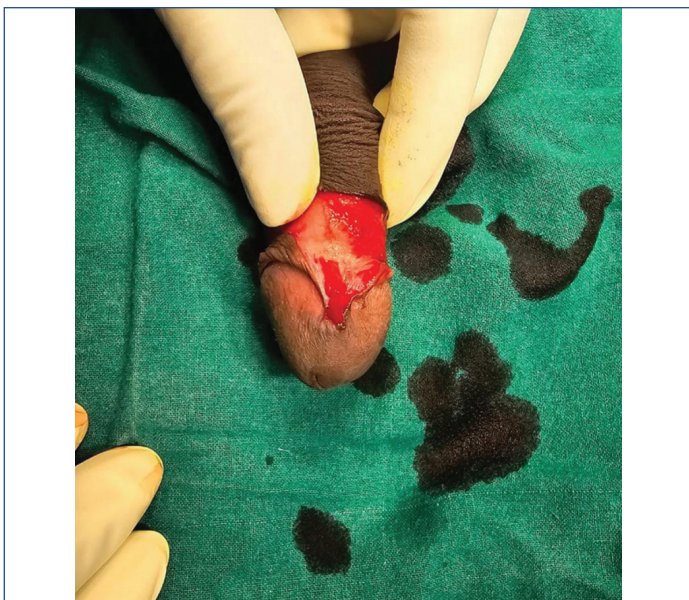


[Table/Fig-3]: Retraction of prepuce showing paramedian position of supernumerary frenulum.

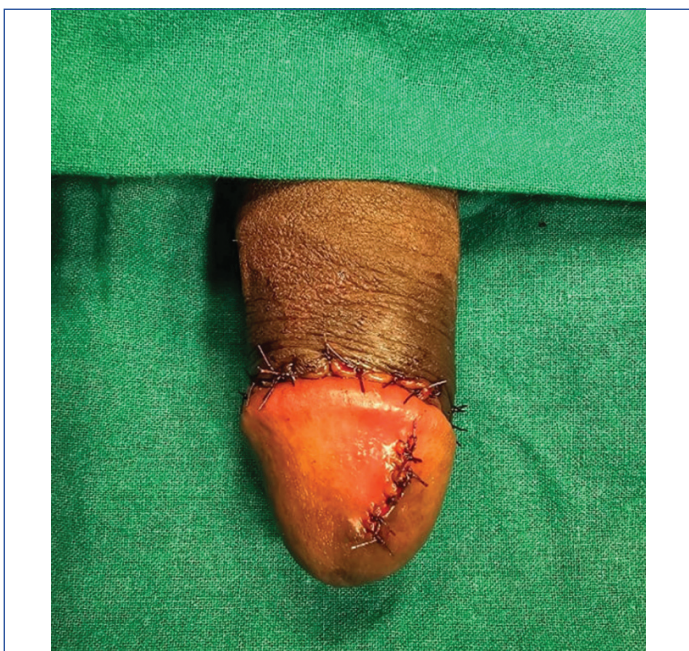Under penile block anaesthesia, the band of tissue on the dorsal aspect of the penis was divided. The foreskin was then retracted to ensure complete division of the band. Subsequently, a formal circumcision was performed. The cut edges of the band were

sutured after achieving haemostasis [Table/Fig-4,5]. The wound healed well, and the patient was satisfied with the result. The patient was followed for three months and did not experience any pain during intercourse.





**[Table/Fig-4]:** Intraoperative picture showing the vascularity and wide base of the supernumerary frenulum.



**[Table/Fig-5]:** Cut edges of the band were sutured after achieving haemostasis.

## DISCUSSION

Supernumerary frenulum of the penis is a rare and underreported anomaly. Awareness of genital anomalies among primary care physicians and paediatricians is uneven and limited. The understanding of the difference between physiological adhesions and phimosis in children is inadequate, even among healthcare professionals [1,2]. This could be the main reason for the limited reporting of supernumerary frenulum of the penis in the literature. Academic training and raising awareness about genital abnormalities are crucial and beneficial for enhancing the detection of these anomalies [3].

Penile torsion is a congenital condition characterised by the rotation of the penile shaft and glans along the longitudinal axis, typically accompanied by a single frenulum in a rotated position. Verneuil first documented this condition in 1857 [4]. While isolated penile torsion occurs with varying frequency (estimated at 2-27%), it remains relatively uncommon [5].

Adhesions that occur following neonatal circumcision can be categorised into two types: congenital and surgical. In newborns, most uncircumcised males have congenital physiological adhesions between the inner preputial skin and the glans. These adhesions gradually disappear as the underlying skin exfoliates, producing

smegma [2]. Postsurgical adhesions sometimes occur as the circumcision wound heals. A scar bridge forms primarily on the dorsal side or circumferentially between the circumcision wound and the glans. These bridges can be almost transparent in infants but thicken with age. Coronal adhesions typically occur in circumcised infants between the ages of two months and six months, and they generally clear up by the time the child reaches 24 months [6].

The preferred treatment is circumcision with division of the accessory frenulum. Accessory frenula vary in their extent and width, making frenuloplasty techniques potentially ineffective for addressing this issue. Simple division can lead to recurrent dense adhesions. Incomplete or traumatic lysis may cause the development of thick and vascular scar tissue [7].

Five cases have been documented in the academic literature [8-12]. Each of these reported cases incidentally found a single supernumerary frenulum alongside a normally positioned one.

Singla SL et al., assert that their report is the first documented case of a dorsal frenulum, followed by subsequent case reports. A 20-year-old male patient presented with penile pain during sexual intercourse. Upon examination, the frenulum was found on the dorsal aspect of the penis rather than the ventral surface. The frenulum was small, and complete retraction of the foreskin caused discomfort. Frenuloplasty was performed [8].

Arora B reported a 24-year-old male patient who experienced painful sexual intercourse. Upon examination, a V-shaped and double-layered band of tissue was found connecting the upper surface of the glans penis to the foreskin. A normal frenulum was present on the underside. Frenuloplasty was performed on the dorsal penile frenulum [9].

Mukendi AM and Doherty SW reported the case of a 31-year-old male trauma patient with a pelvic fracture and right scrotal laceration who had a completely asymptomatic dorsal frenulum. The patient stated that he had an extra band of tissue on the upper surface of his penis, in addition to the normal band on the underside, even before he underwent traditional circumcision at the age of 10 years. There was no history of painful intercourse. Examination revealed two bands connecting the glans to the distal penile shaft, one on the dorsal aspect and the other on the ventral aspect [10].

Goyal SK et al., reported a 17-year-old, sexually inactive male patient who presented with concerns about the unusual appearance of his penis. He had a history of occasional painful, spontaneous nocturnal erections that were severe enough to wake him from sleep. Examination revealed a normal ventral frenulum and an additional band of tissue between the dorsolateral aspect of the glans and the prepuce at the 10 o'clock position. The patient was diagnosed with a double frenulum and underwent a frenuloplasty to address the aberrant frenulum [11].

Fernandes MP et al., documented a case with two supernumerary frenula. A 17-year-old Brazilian male experienced pain and discomfort when trying to retract his foreskin for hygiene and masturbation. Examination revealed the presence of two additional frenula, one on each side of the penile glans, in addition to the normal ventral frenulum. Frenuloplasty of the extra frenula and division of the ventral frenulum, followed by circumcision, was performed [12].

The histological characteristics of the preputial mucosa differ from those of regular skin, reflecting its specialised functions. Unlike the multilayered epidermis with keratinocytes found in preputial skin, the preputial mucosa is softer and more pliable, as it does not undergo the same level of keratinisation. There is a higher concentration of specialised sensory structures, such as Meissner's corpuscles, which are sensitive to light touch, in the preputial mucosa compared to the fewer numbers present in preputial skin. The preputial mucosa and the frenulum exhibit similarities in terms of mucosal properties, nerve supply and blood flow. However, the frenulum is distinguished by its greater flexibility and its function as a stabilising element [13].

## CONCLUSION(S)

Proactive identification and understanding of genital abnormalities are crucial for proper diagnosis and management. Complete surgical circumcision is preferred over a simple division of the supernumerary frenulum. The identification and separation of physiological adhesions can be performed after the age of three. Religious circumcisions using the guillotine method often neglect underlying genital anomalies and should be replaced with formal surgical circumcisions conducted by trained professionals.

## REFERENCES

- [1] Mahalik SK, Pati AB, Das K. Awareness of common paediatric surgical entities among practicing Indian paediatricians. *J Indian Assoc Paediatr Surg.* 2021;26:89-93.
- [2] Kumar P, Deb M, Das K. Preputial adhesions--a misunderstood entity. *Indian J Paediatr.* 2009;76:829-32.
- [3] Mazen I, El-Ruby M, Kamal R, El-Nekhely I, El-Ghandour M, Tantawy S, et al. Screening of genital anomalies in newborns and infants in two egyptian governorates. *Horm Res Paediatr.* 2010;73:438-42.
- [4] Verneuil M. Torsion congenitale du penis avec hypospadias. *Bullerin de La Socete de Chirurgie de Paris.* 1857;8:68-70.
- [5] Zvizdic Z, Milisic E, Vranic S. Penile degloving and dorsal dartos flap rotation surgery in the management of severe isolated penile torsion in a 6-year-old boy. *Acta Medica (Hradec Kralove).* 2020;63(1):52-54.
- [6] Van Howe RS. Variability in penile appearance and penile findings: a prospective study. *Br J Urol.* 1997;80:776-82.
- [7] Goel P, Bajpai M. An unusual complication of preputial adhesiolysis: From flimsy adhesions to bridging adhesions. *Pediatr Urol Case Rep.* 2019;6(1):08-12.
- [8] Singla SL, Garg P, Bishnoi PK, Singh B. Dorsal penile frenulum. *Urol Int.* 1997;59:55-56.
- [9] Arora B. Dorsal penile frenulum: A rare developmental abnormality. *Int J Case Rep Imag.* 2016;7(5):311-13. Available from: <https://doi.org/10.5348/ijcri-201654-CR-10642>.
- [10] Mukendi AM, Doherty SW. Dorsal penile frenulum a rare congenital abnormality. *Afr J Urol.* 2019;25(1):NA. Available from: <https://doi.org/10.1186/s12301-019-0001-6>.
- [11] Goyal SK, Gupta S, Gupta S. Double-penile frenulum: An unusual developmental anomaly. *Current Medical Issues.* 2020;18(4):332-33.
- [12] Fernandes MP, Ferreira MG, de Figueiredo Ramalho S, de Carvalho Junior AM. Supernumerary penile frenulum: a rare description in the literature. *Acta Scientiae Anatomica.* 2020;1(4):244-47.
- [13] Taylor JR, Lockwood AP, Taylor AJ. The prepuce: specialized mucosa of the penis and its loss to circumcision. *Br J Urol.* 1996;77:291-95.

### PARTICULARS OF CONTRIBUTORS:

1. Chief Civil Surgeon, Department of Plastic Surgery, Government District Headquarters Hospital, Kumbakonam, Tamil Nadu, India.

### NAME, ADDRESS, E-MAIL ID OF THE CORRESPONDING AUTHOR:

Prabhakar Ulaganathan,  
70, Jaganatha Pillayar Koil West Street, Kumbakonam-612001, Tamil Nadu, India.  
E-mail: drprabhakarplastic@hotmail.com

### PLAGIARISM CHECKING METHODS: [Jan H et al.]

- Plagiarism X-checker: Jul 29, 2024
- Manual Googling: Sep 10, 2024
- iThenticate Software: Sep 17, 2024 (6%)

### ETYMOLOGY: Author Origin

EMENDATIONS: 6

### AUTHOR DECLARATION:

- Financial or Other Competing Interests: None
- Was informed consent obtained from the subjects involved in the study? Yes
- For any images presented appropriate consent has been obtained from the subjects. Yes

Date of Submission: **Jul 29, 2024**  
Date of Peer Review: **Sep 11, 2024**  
Date of Acceptance: **Sep 18, 2024**  
Date of Publishing: **Nov 01, 2024**